

# Direct bimaxillary rehabilitation on Prama implant

Dr. Costantino Vignato, Dr. Giuseppe Vignato, D.T. Riccardo Finotello, Vicenza, Italy

Male patient with severe bone resorption in both arches.

Complete rehabilitation of both arches with a composite Toronto prosthesis directly screw retained on Prama implants. Following the extraction of the damaged teeth, five Prama RF implants are inserted in the upper arch while five Prama and Prama RF implants are inserted in the lower arch.

---

**“There are at least three reasons to consider Prama a more effective implant for complex rehabilitations of a dental arch:**

- 1. The respect of crestal bone anatomy**
- 2. The conical emergence adaptation to bone irregularities**
- 3. No need to use intermediate angled abutments**

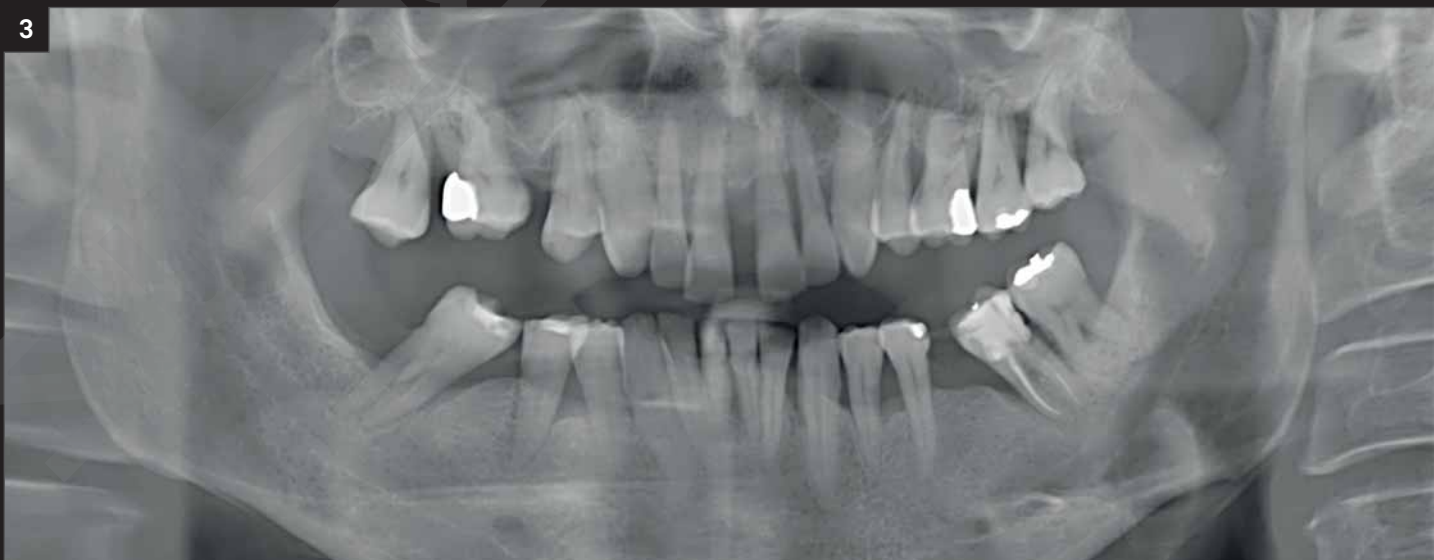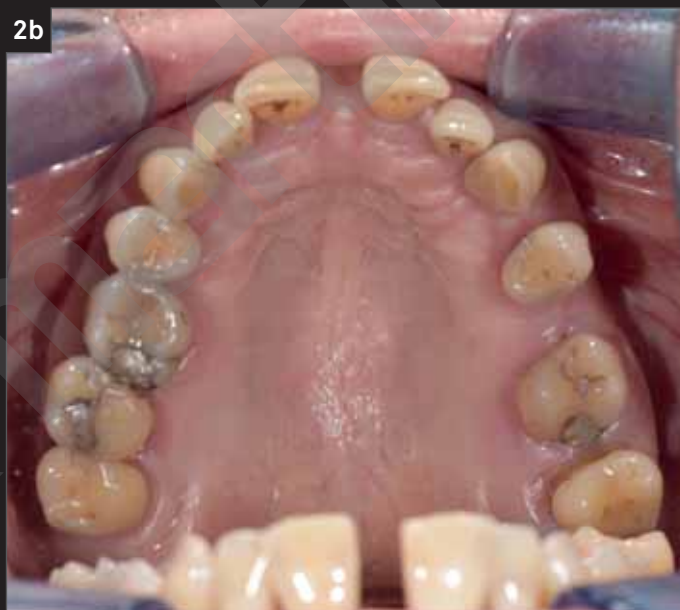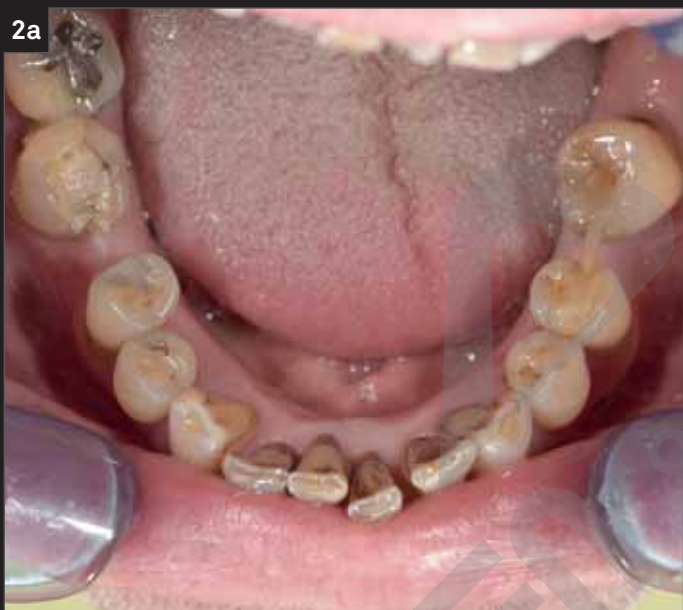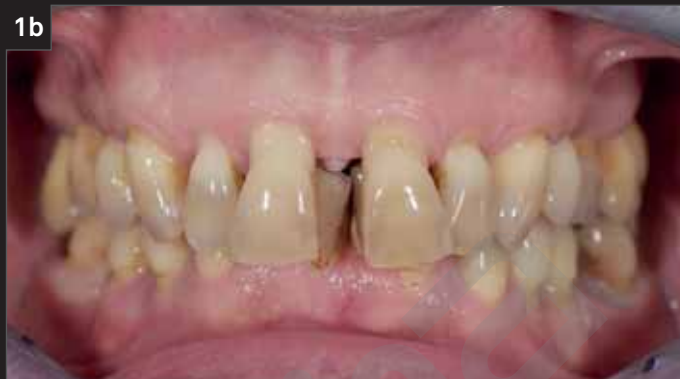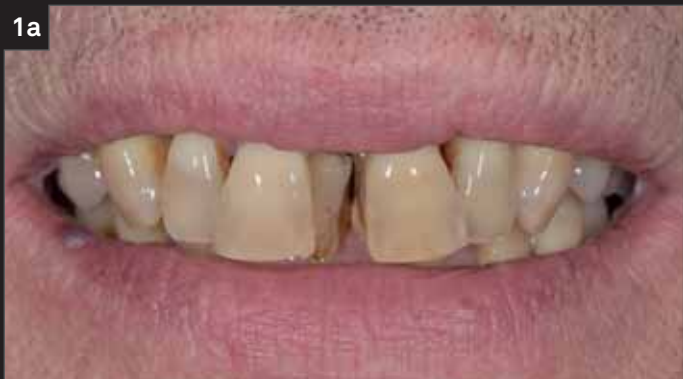This means a minimally invasive surgery, faster healing and still there is the possibility to insert the implants in an angled position.

The rehabilitation of a dental arch on Prama implants allows the clinician to set the prosthetic structure at a distance of at least 2.8 mm from the osseointegration area, thereby forming a gingival protection area and a soft tissue support capable of guaranteeing easy cleaning and aesthetic stability over time.

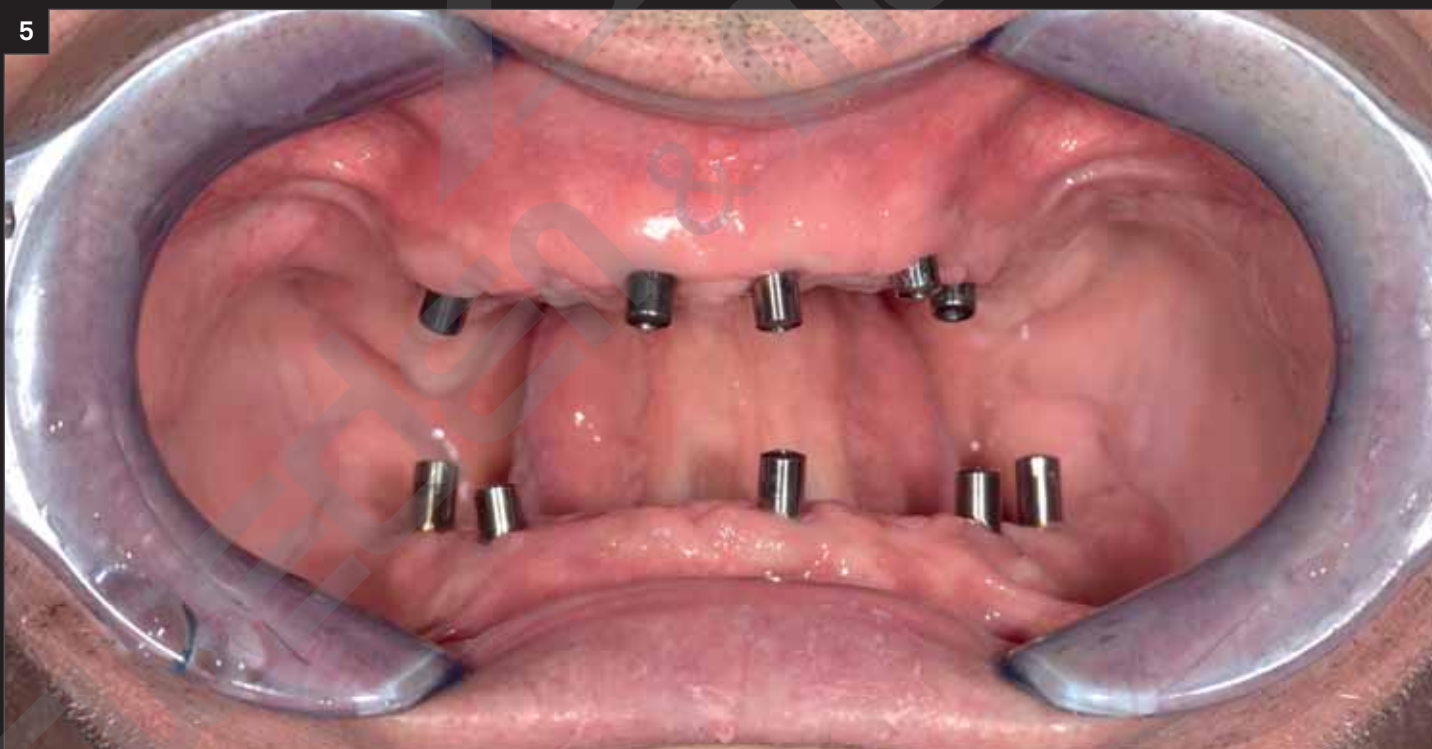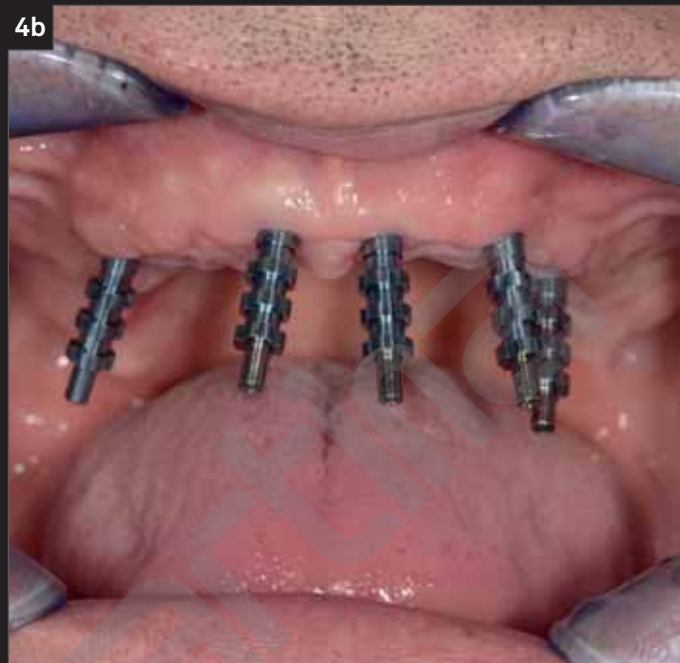
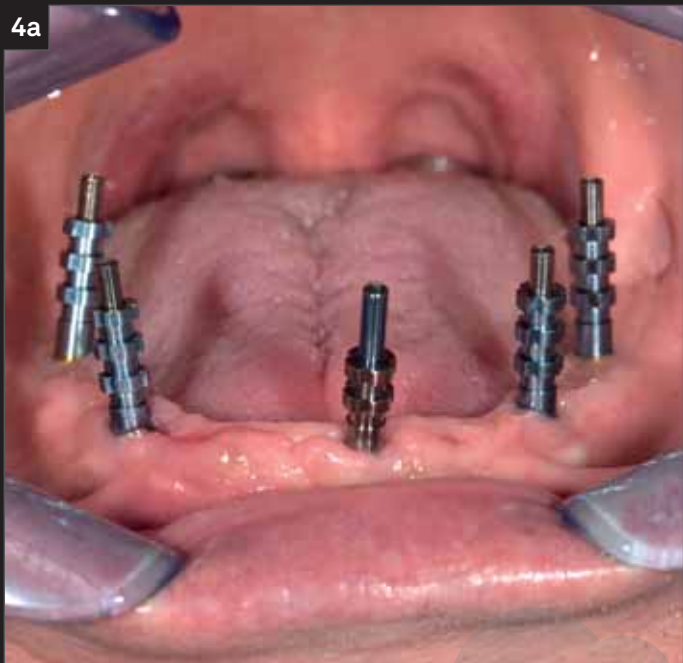
Moreover, combining the gingival healing potential on the convergent neck with the use of modern connective membranes, now it is possible to obtain prostheses which are ‘ALL WHITE’ or with a minimal portion of pink, with a minimally invasive approach.”

(cit. Dr. Costantino and Dr. Giuseppe Vignato)

---



1. Initial situation: bone resorption is evident both in the maxilla and mandible.
2. Occlusal view of the preoperative case in which the resorption, both vestibular and lingual, of the lower arch is evident. The movement of elements 2.4 and 2.6, following the loss of 2.5, also is noticeable.
3. Initial radiographic control.

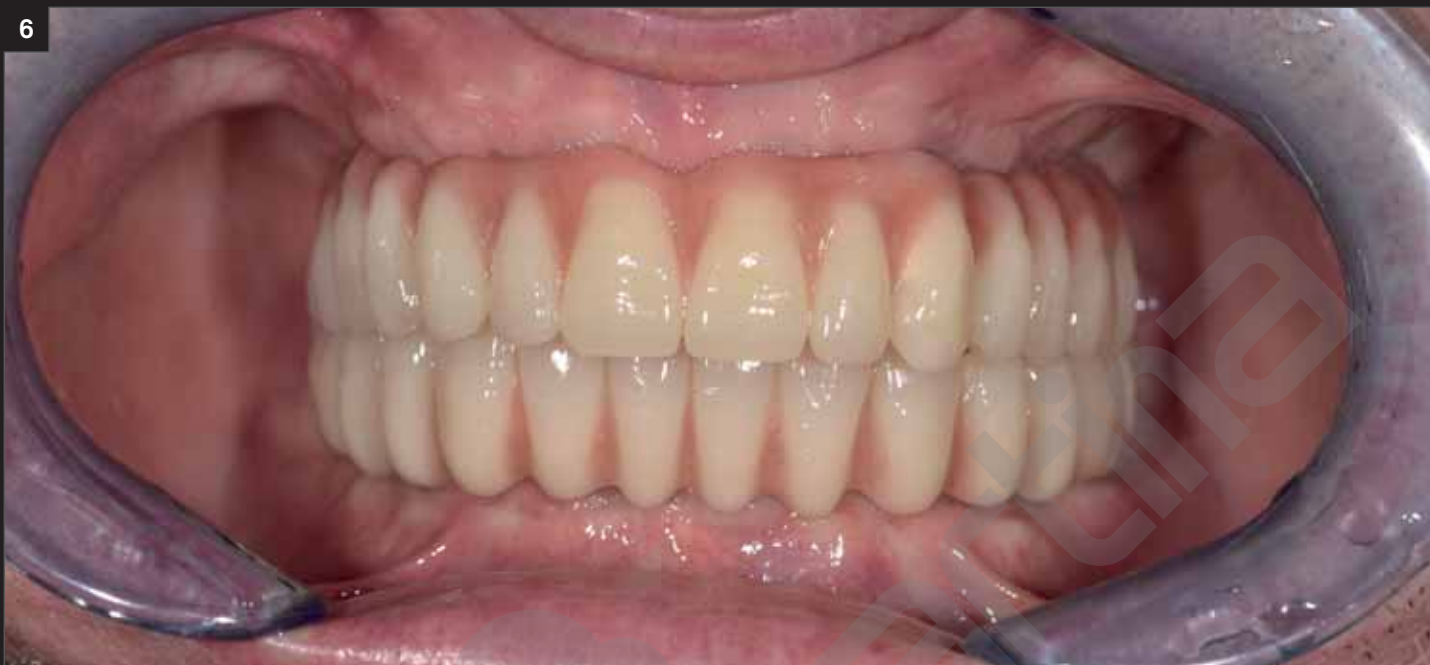

4. Open tray impression with Pick-up transfer.

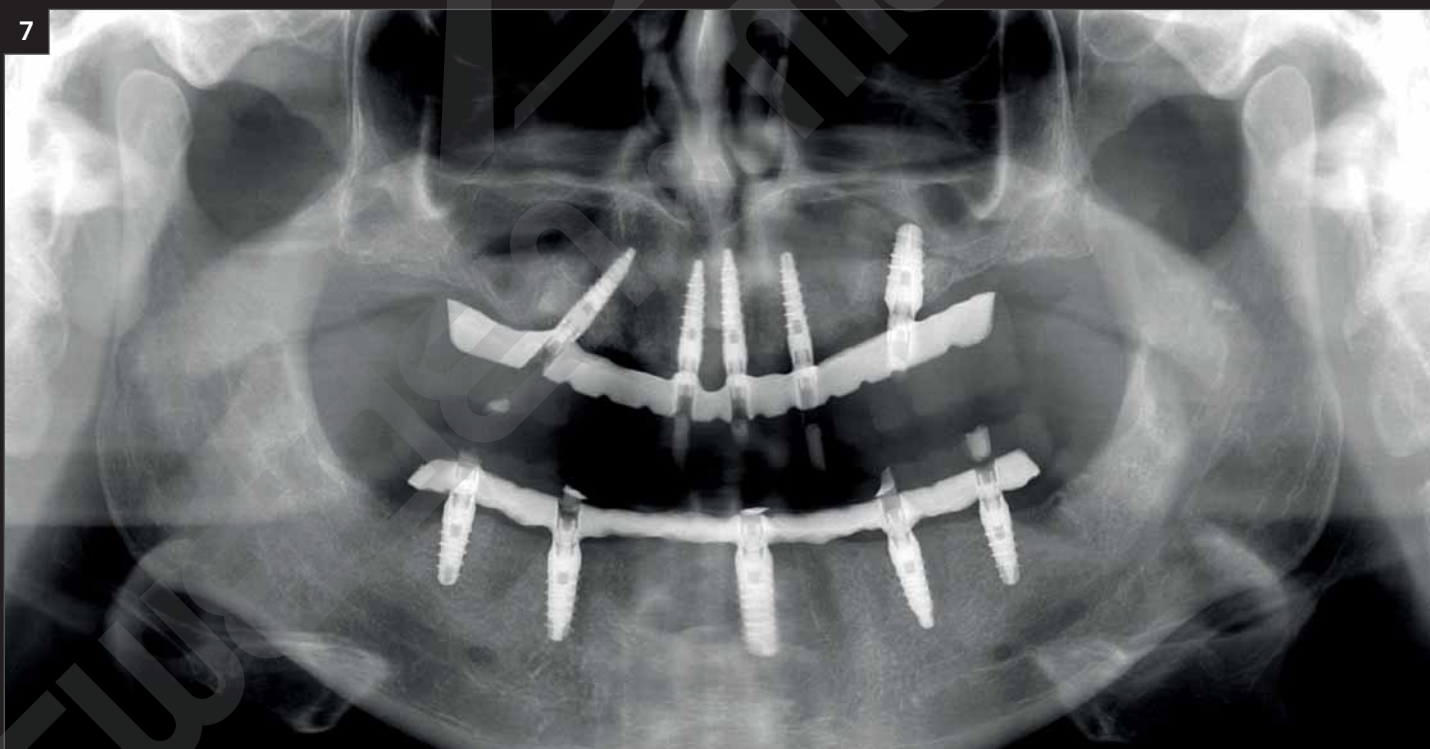5. Clinical situation 3 months after surgery in the upper and lower arch.



6



7



6. Final aspect of the rehabilitation.

7. Final radiograph.

Ask for your free copy of the book

# PRAGMATICO

at this [link](#)