

# All on Prama with Simple Technique

Dr. Marco Csonka, Catania, Italy

Female patient, 55 years old, no previous systemic pathological records. The patient had severe periodontal damage of the residual elements of the upper arch. It was decided for immediate post-extraction rehabilitation with immediate loading and to proceed with the Simple protocol, which includes the following steps:

1. **Pre-surgery examination** (orthopantomography, photograph, models, facial arch, aesthetic and phonetic tests, gnathological evaluation);
2. **Oral cavity preparation** (tartar ablation, scaling, laser decontamination, preliminary extraction of teeth with purulent infections);
3. **Surgical phases:**
  - extractions and extreme alveolar curettage;
  - disinfection with Betadine;
  - mucoperiosteal flap (if indicated);
  - reduction osteoplasty (if indicated);
  - implant insertion;
  - P.A.D. mounting (straight and angulated);
  - GBR if necessary;
  - suture;
  - temporary posts mounting;
  - posts fastening with Sun resin.

Sterile phase

---

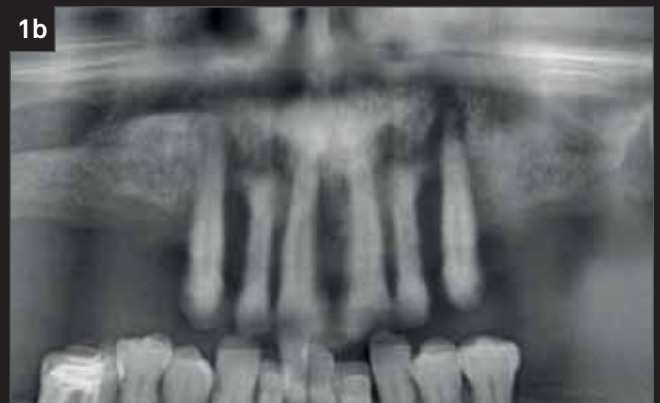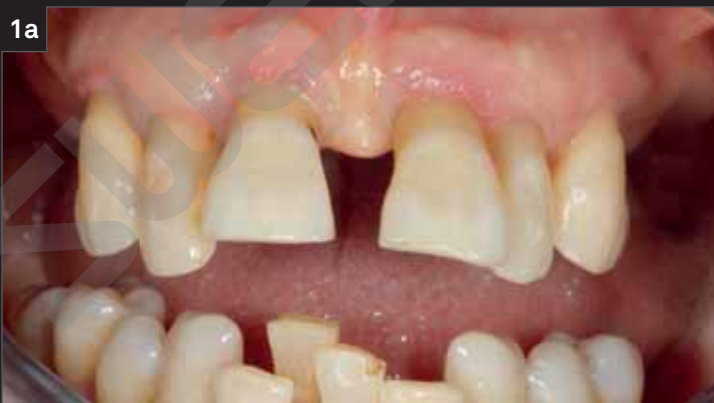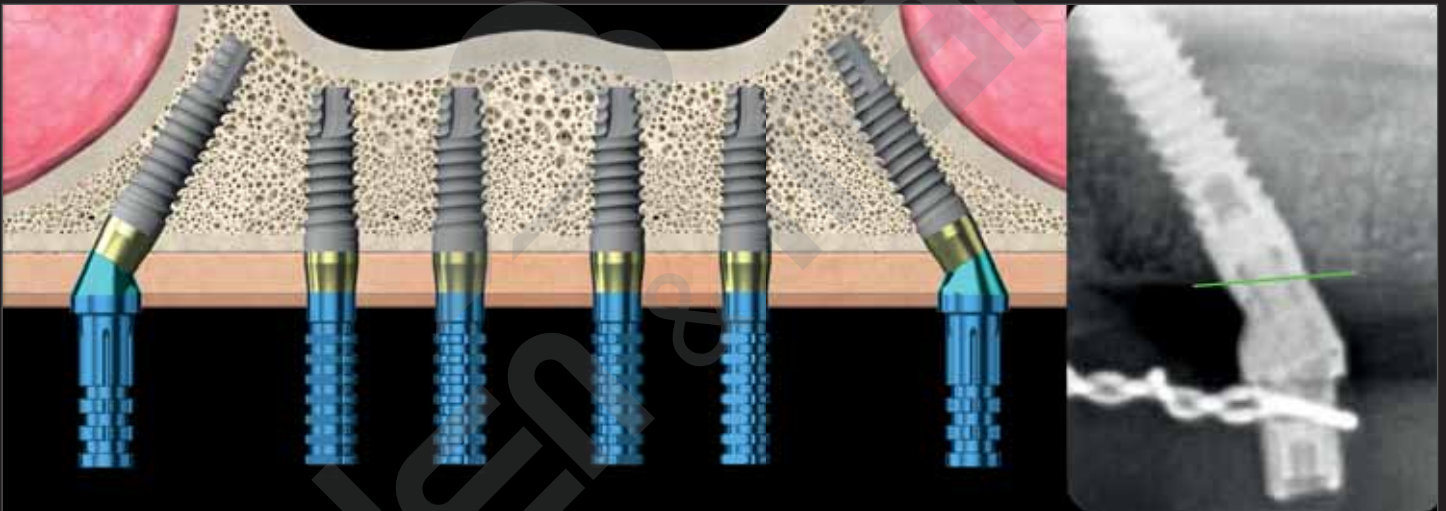
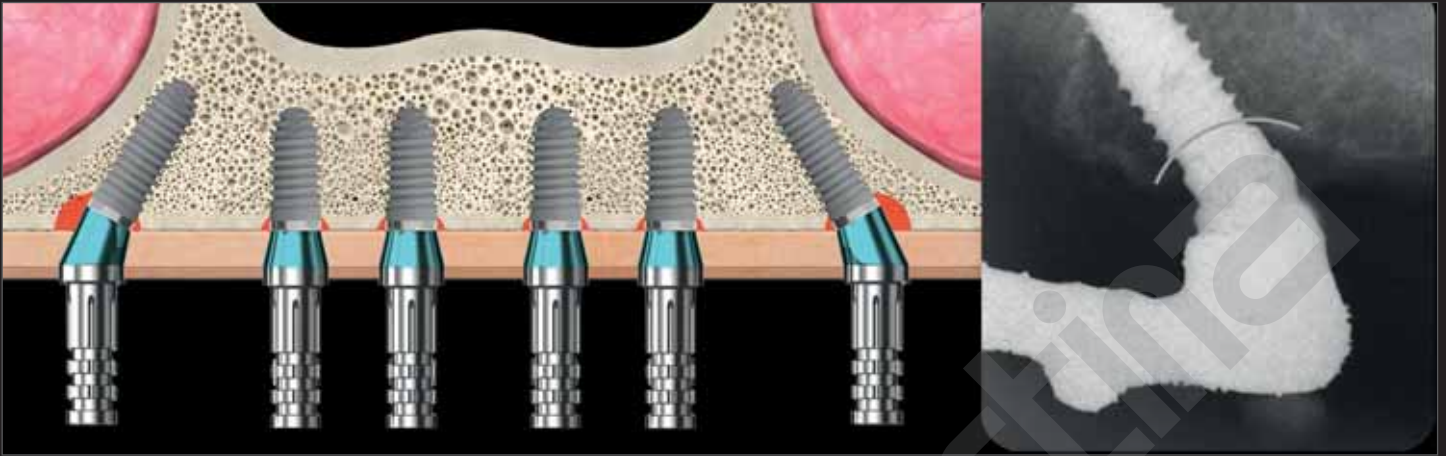
**“In immediate post-extraction full arch rehabilitation with immediate loading the benefits of using Prama implants are:**

- **in the posterior tilted implants, the intra- and post- operative preservation of the crestal bone and the prevention of bone resorption cones (unfortunately unavoidable with bone level implants);**
- **the possibility of reducing or eliminating regenerative procedures around post-extraction implants, since the gap between the UTM neck of Prama and the residual walls of the alveolus does not need to be filled;**
- **the possibility of reducing the invasive osteoplastic procedures (where not indicated for other reasons), given that the UTM neck of Prama well adapts to the ridges irregularities, offering the clinician the possibility of being inserted more or less out of the ridge.”**

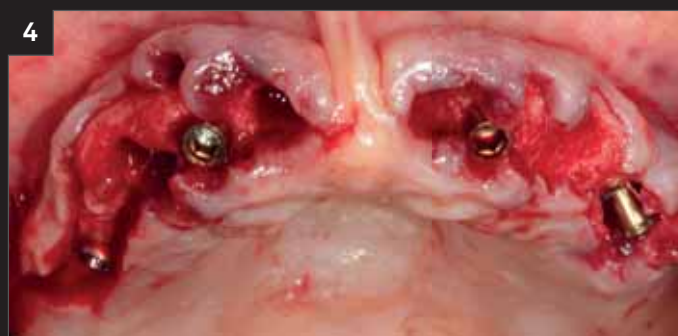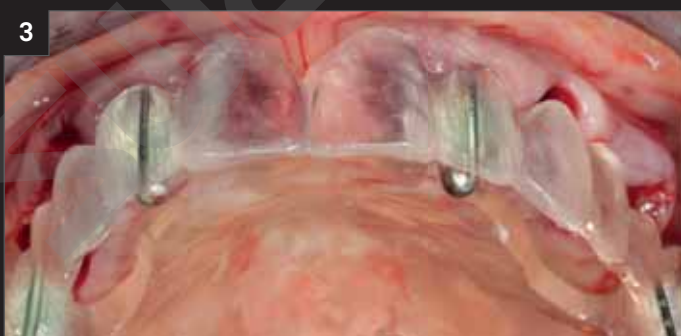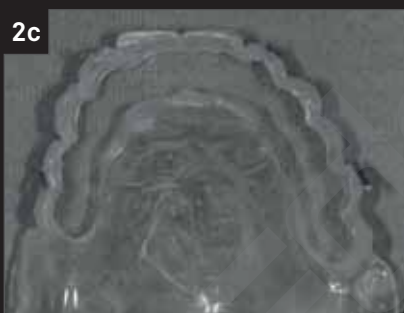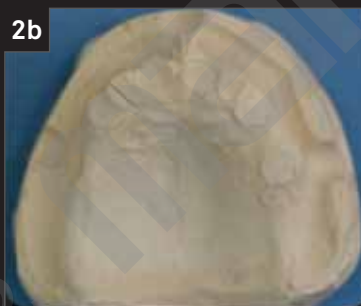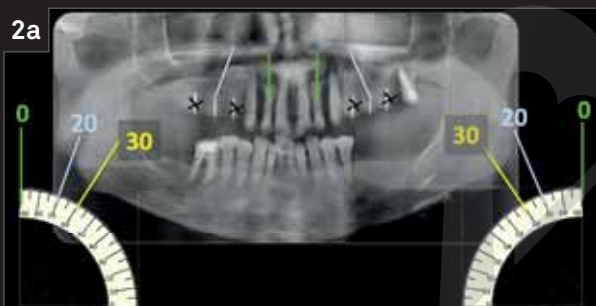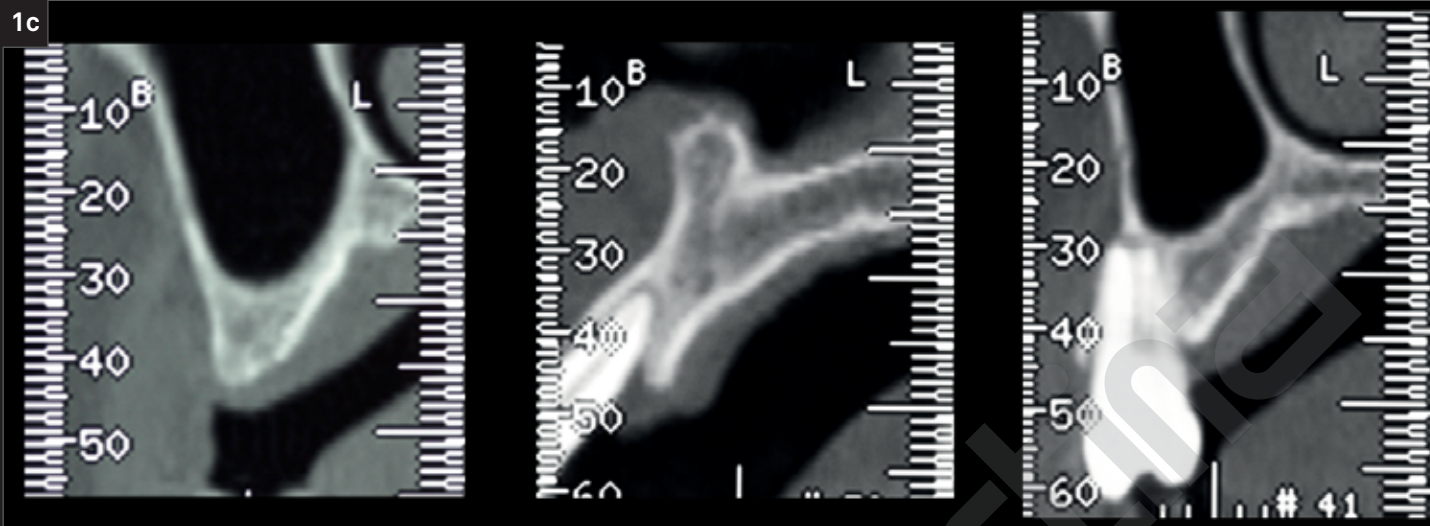
(cit. Dr. Marco Csonka)

---

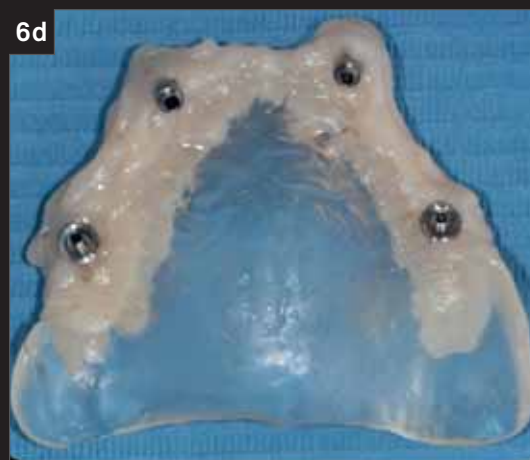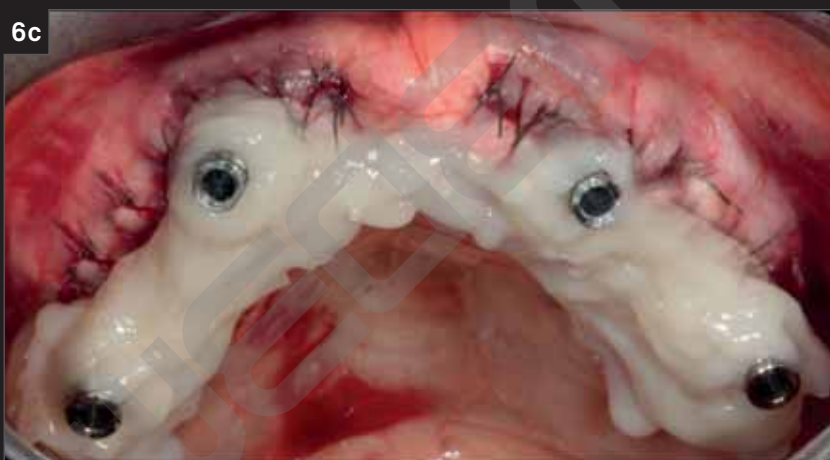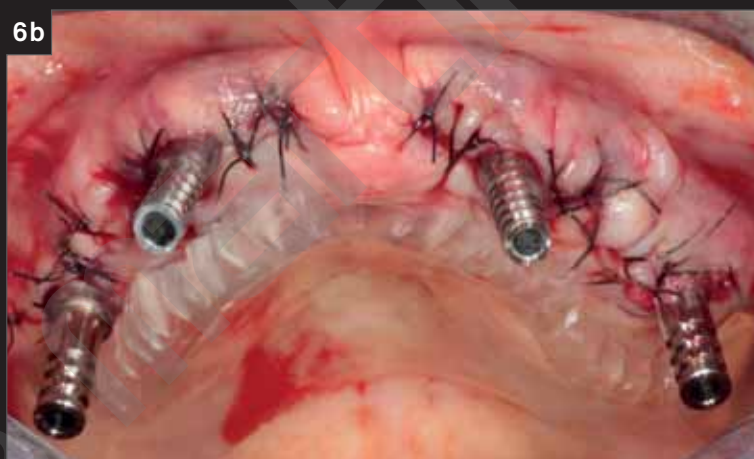
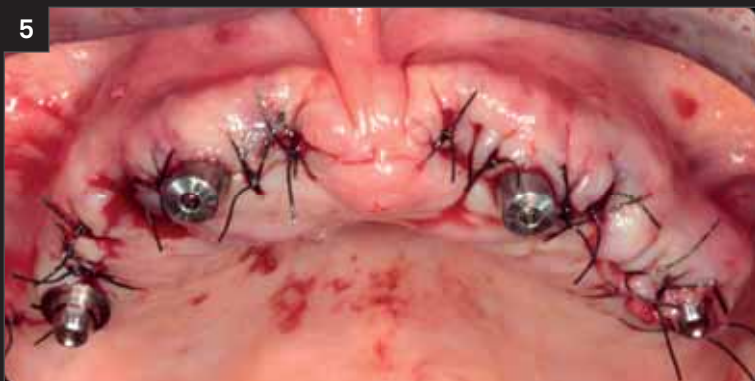Comparison between a full arch maxillary rehabilitation with distal tilted implants with traditional bone level implants (above) and with Prama implants (below).



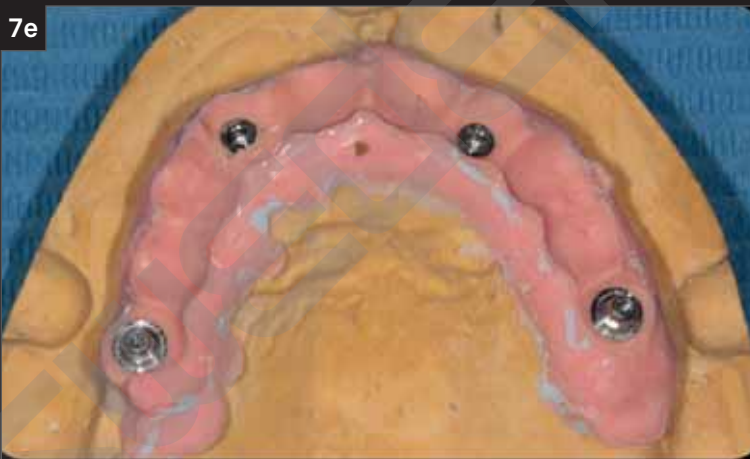
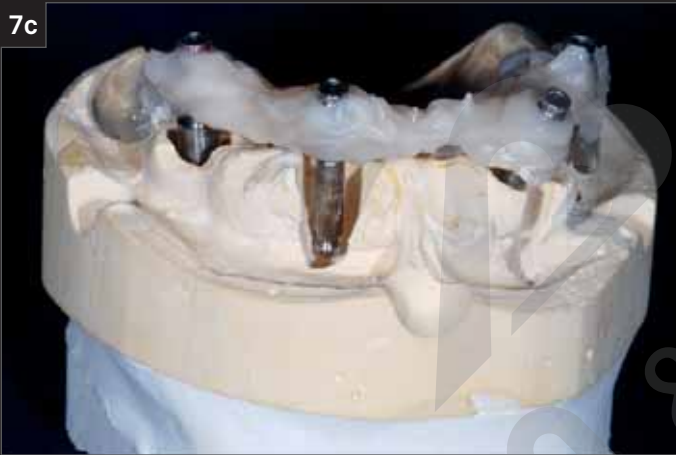
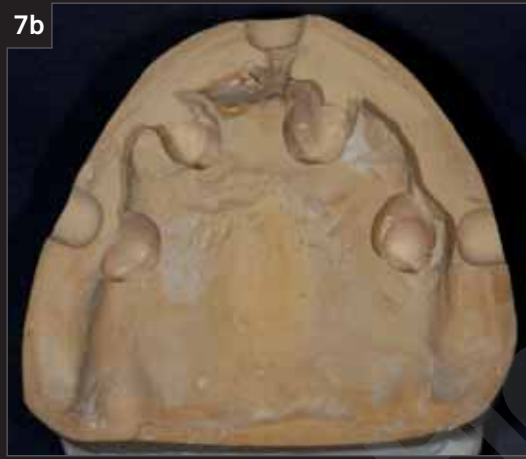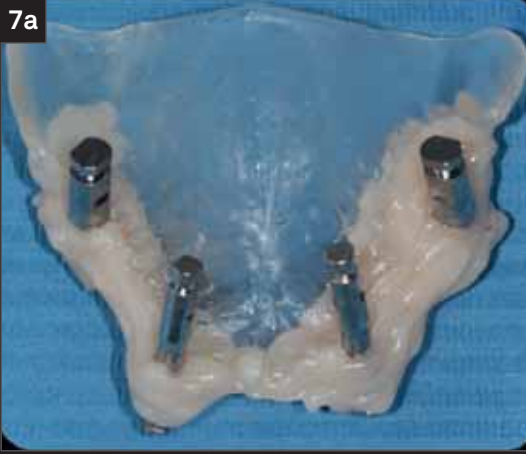1. Pre-operative situation with severe aesthetic and periodontal damage.



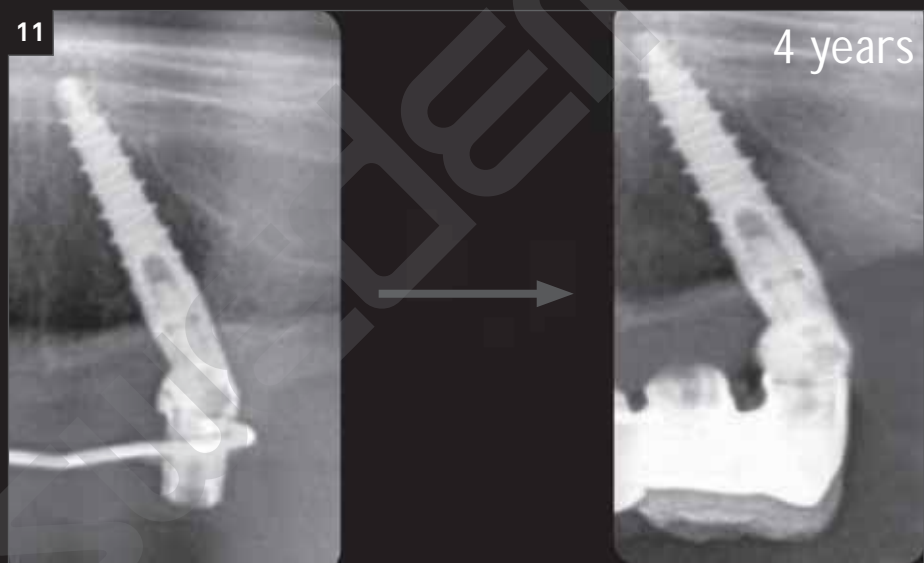
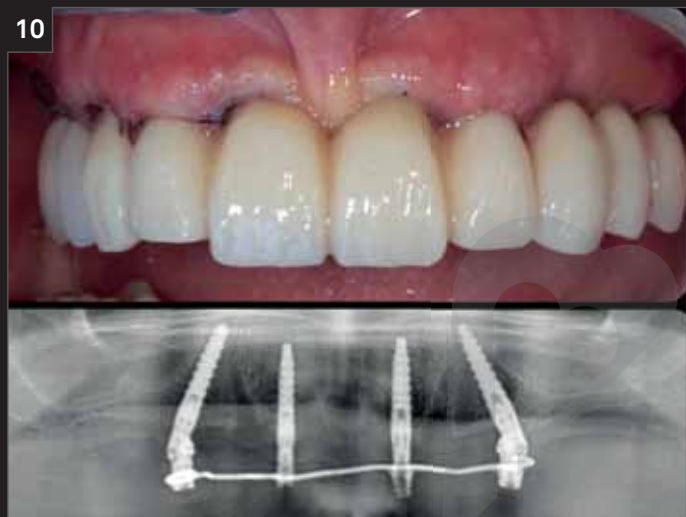
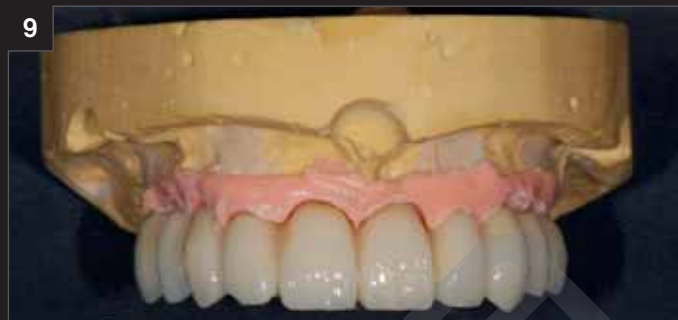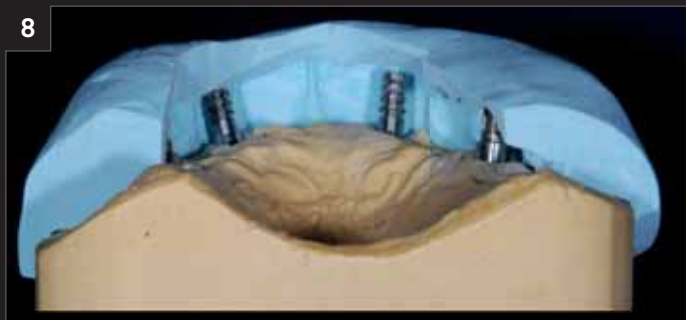2. “Computer free” design according to the Simple Technique: a template prepared by the laboratory reproduces the diagnostic wax-up and has radiopaque marks to decide, with an orthopantomography performed with the template in place, which positions and which inclinations to give to the implants.
3. Positioning of “Simple” template, with the implant sites already drilled and the parallelism pin in place.
4. Four Prama implants just inserted (All on Prama). Note the correct position of the Prama neck of the tilted implants: the distal margin of the neck is 0.5 mm outside the ridge and the mesial margin of the neck will be as much off the ridge as the implants will be angled (see also introductory images).



5. Once the hermetic sutures around the P.A.D. are finished, the sterile phase of the Simple protocol ends, and the prosthetic phases begin. We underline the advantage of having all prosthetic connections outside the gingiva, thanks to Prama neck in association or not with straight or angulated P.A.Ds.
6. We use a resin to bond to a transfer plate the non-engaging titanium sleeves that we will use to produce the immediately loaded temporary prosthesis. In our experience, this technique is more precise, more passive and cleaner than intraoperative impression taking technique.



- 
7. With the single-model technique we use the same master model mounted on the articulator and, not casting a second model, we are able to be precise, passive and always effective.



8. The immediately loaded temporary prosthesis is made in the laboratory, maintaining the same aesthetic, occlusal and phonetic parameters that led to the creation of the “Simple” template.
9. The immediately loaded temporary prosthesis on the master model.
10. The “Simple” temporary restoration delivered within 24 hours and the related radiographic control.
11. Comparison between the immediate post-operative radiographs and the 4-years follow up radiograph. Note the complete stability of the crestal bone, even in the most difficult position, around the tilted distal implant. Signs of neo-corticalization are visible, which are very frequent according to our experience with Prama implants.

Ask for your free copy of the book

# PRAGMATICO

at this [link](#)